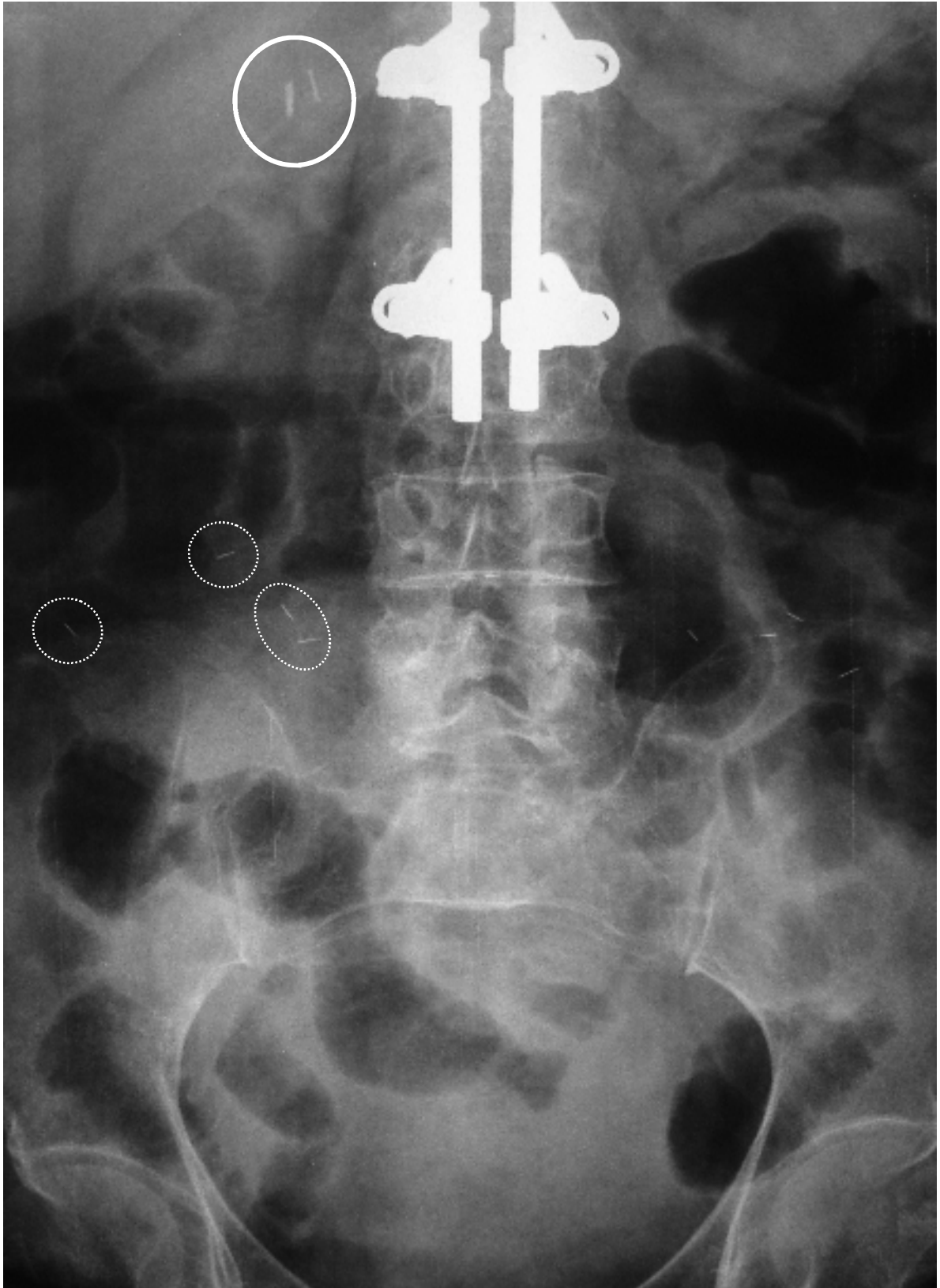


Images of Interest: Supplementary text



The magnified images shows three types of foreign body. The most obvious foreign body is the **spinal prosthesis**. The **cholecystectomy clips** (circle) are seen in the right upper abdomen lateral to the spinal prosthesis. Multiple thin and short linear opacities are **charm needles (susuk)**, some of which are highlighted by broken circles.