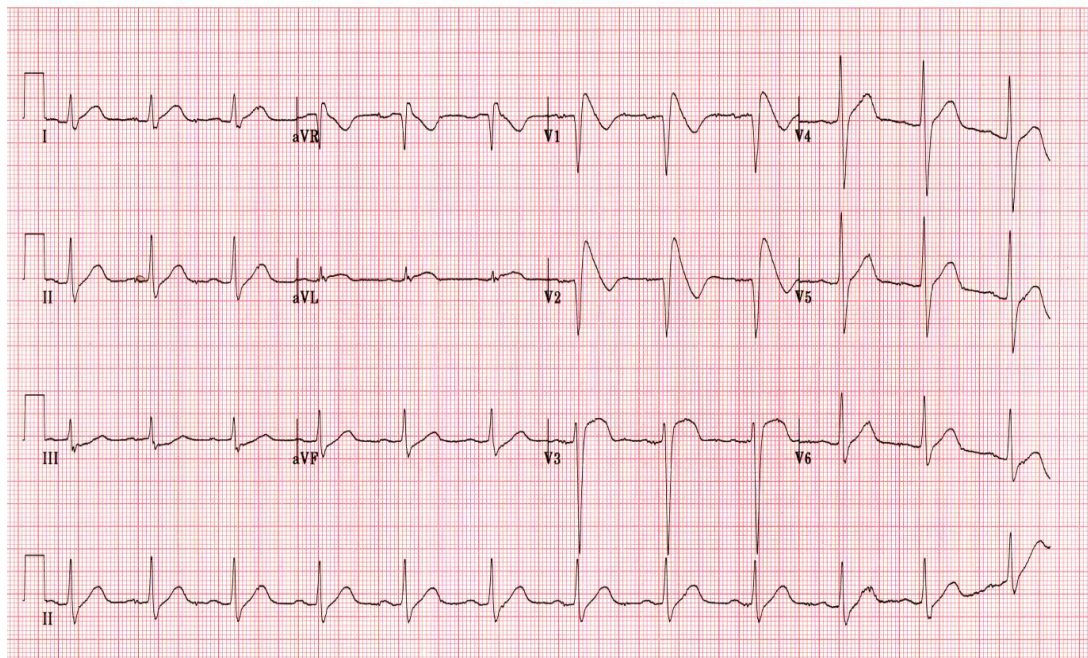


Nazar LUQMAN

A 34-year-old male with diabetes mellitus presented with diabetic ketoacidosis. He was treated with insulin. Echocardiography and cardiac enzymes (CKMB and troponin I) were normal. Routine electrocardiogram (ECG) was done and is shown in the above panel.

Q: What is the ECG diagnosis?

What are the possible diagnoses you would consider?

- 1: Acute ST segment elevation myocardial infarction (STEMI)
- 2: Hyperkalemia
- 3: Brugada Syndrome
- 4: Normal ST-T changes in a young person

Answer: refer to page 69

Correspondence author: Hj Nazar LUQMAN,
Division of Cardiology, Department of Medicine,
RIPAS Hospital, Bandar Seri Begawan BA 1710,
Brunei Darussalam.
Tel: +673 8816326
E mail: nazarluqman@gmail.com