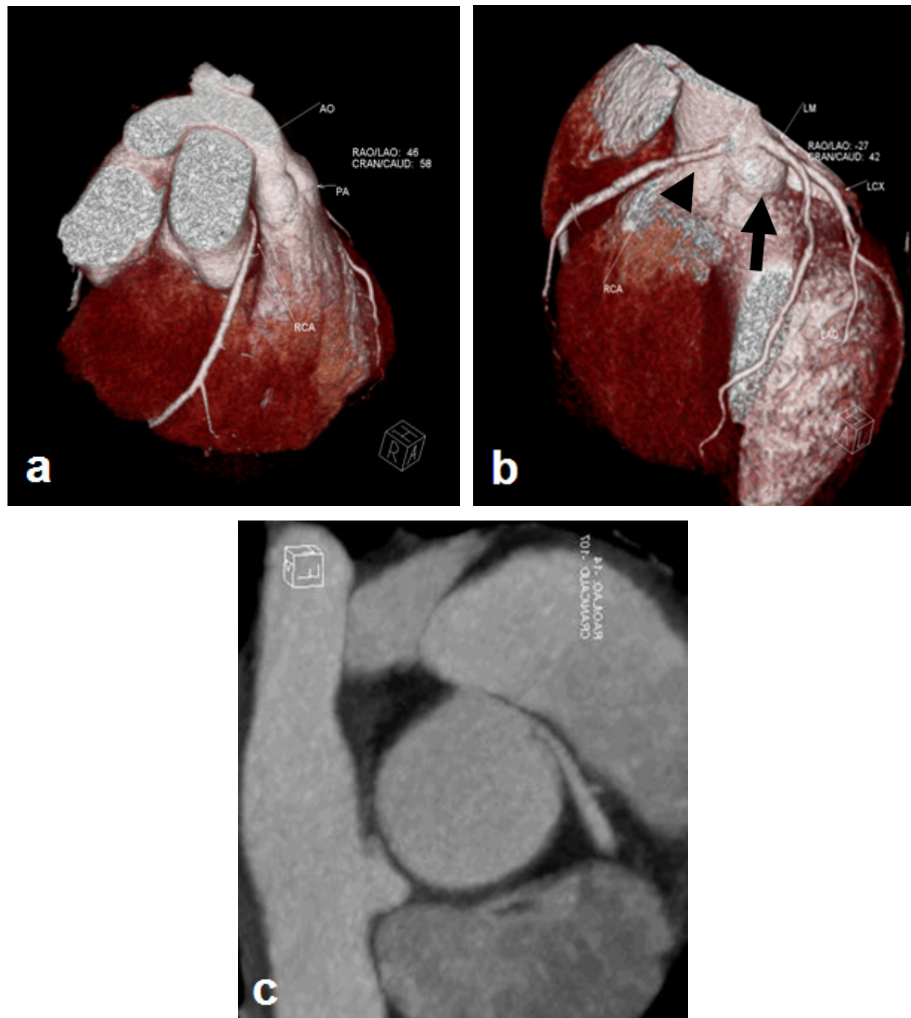


Nazar LUQMAN



A 42-year-old male presented with a history of presyncope. There was no postural hypotension or neurological cause for syncope. Electrocardiogram (ECG) only showed non-specific ST-T changes in inferior leads. Echocardiogram, exercise stress test and 24 hours holter monitoring were all normal. Computed tomography (CT) angio was done and are shown in the panels above.

Q: What is the diagnosis?

Answer: refer to page 71

Correspondence author: Hj Nazar LUQMAN,
Division of Cardiology, Department of Medicine,
RIPAS Hospital, Bandar Seri Begawan BA 1710,
Brunei Darussalam.
Tel: +673 8816326
E mail: nazarluqman@gmail.com