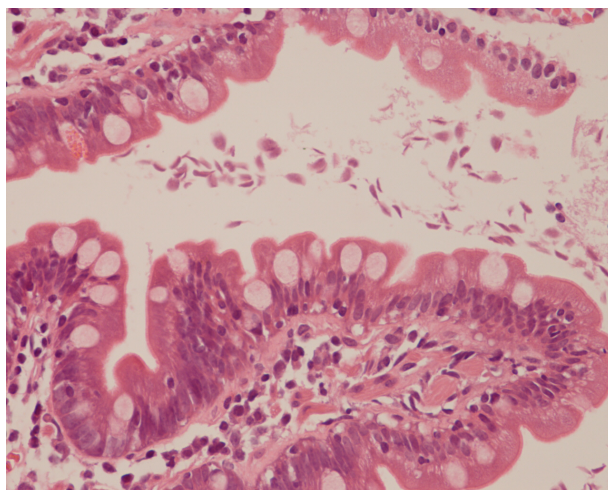


Sowmya Tatti RAJARAM, Ghazala KAFEEL, Pemasiri Upali TELISINGHE, Hla OO



A 35-middle-aged female with history of recent travel to the Indian Subcontinent, presented with features of malabsorption. Blood chemistry revealed low serum albumin and low serum Vitamin B12 levels. Upper gastrointestinal endoscopy was done and was reported as normal. The duodenal biopsy sent for histopathologic examination and is shown (**Panel**).

What is the diagnosis?

Answer: refer to page 186

Correspondence author: ST RAJARAM,
Department of Pathology,
RIPAS Hospital, Bandar Seri Begawan BA1710,
Brunei Darussalam.
Tel: +673 2242424, Ext 7356
E mail: sowmya.kulkarni@rediffmail.com