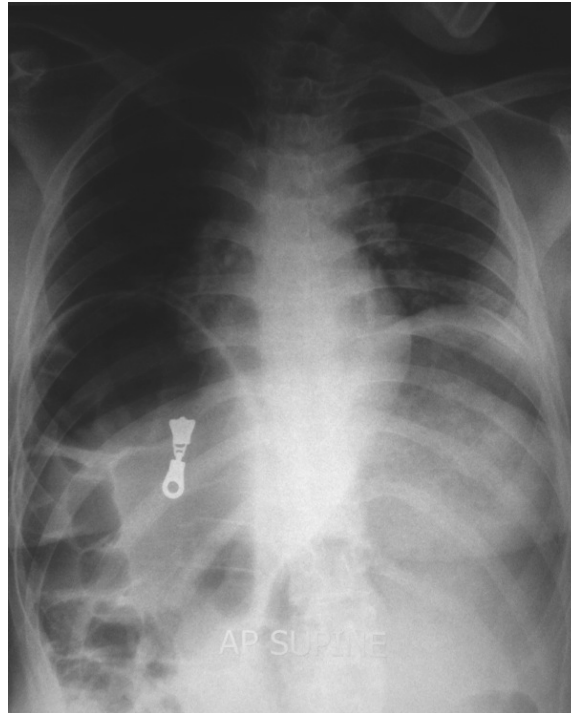


**Pei Yee ONN, Norwani BASIR, Vui Heng CHONG**



A young lady presented with recurrent abdominal distention and pain. Over the past few years, she had been admitted several times with similar complaints. Each time the symptoms settled with conservative management. Abdominal radiography (**Panel**) on admission is shown above.

**What does the radiograph show and what is the syndrome ?**

**Answer:** refer to page 187

**Correspondence author:** Vui Heng CHONG  
Department of Medicine  
RIPAS Hospital, Bandar Seri Begawan BA 1710,  
Brunei Darussalam.  
Tel: +673 2242424 Ext 5233  
E mail: chongvuih@yahoo.co.uk