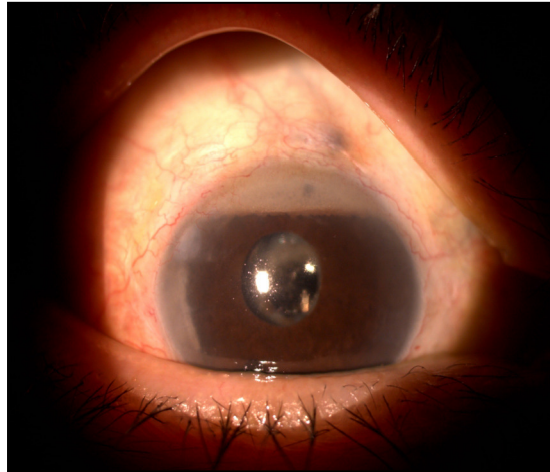


**Nadir Ali MOHAMED ALI, Mohan RAMALINGAM, Nayan JOSHI**



A 63-year-old lady with a history of type 2 diabetes mellitus for 32 years presented with blurring of vision and whitish spot in the right eye. She gave a history of previous laser treatment in both eyes and multiple eye surgeries in the right eye. Ophthalmic examination is shown above **(Panel)**.

**What is the diagnosis?**

**Answer:** refer to page 350

**Correspondence author:** NA MOHAMED ALI  
Department of Ophthalmology  
RIPAS Hospital, Bandar Seri Begawan BA 1710,  
Brunei Darussalam.  
Tel: +673 8223690  
E mail: nadiramali@hotmail.com