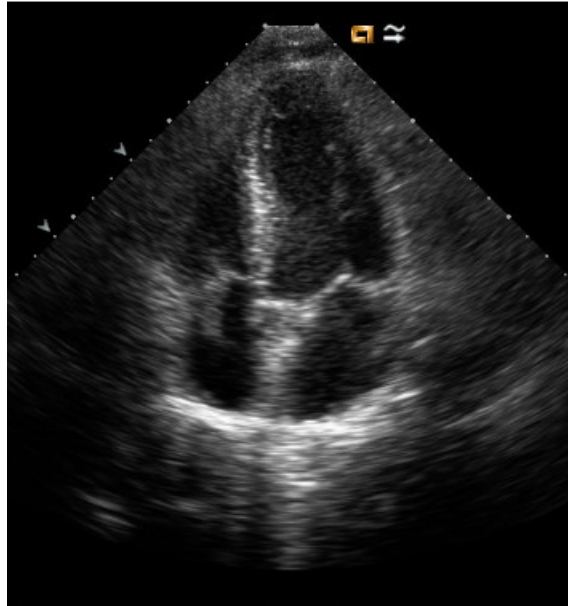


**Ezam EMRAN and Nazar LUQMAN**



A young man presented with high-grade fever. Clinical examination revealed a loud systolic murmur at the lower sternal edge. He is otherwise fit and well with no significant past illnesses. He does, however, have a history of intravenous drug abuse. An echocardiogram was done (**Panel**). (To watch the video please go to the online version and click on the image).

**What is the abnormality and what is the diagnosis?**

**Answer:** refer to page 59

**Correspondence author:** Ezam EMRAM,  
Division of Cardiology, Department of Medicine,  
RIPAS Hospital, Bandar Seri Begawan BA 1710,  
Brunei Darussalam.  
Tel: +673 2242424  
E mail: ezam.emran@gmail.com