

# Porcelain gallbladder: The rare end of the spectrum of chronic cholecystitis

**Mohannur Sukanathan MATHIAZHAGAN, Anand JALIHAL, Vui Heng CHONG**  
Division of Gastroenterology and Hepatology, Department of Medicine,  
RIPAS Hospital, Brunei Darussalam.

## ABSTRACT

Porcelain gallbladder is an uncommon manifestation of chronic cholecystitis. The wall of the gallbladder becomes hard, calcified and brittle with a bluish-white tinge which resembles a porcelain ceramic. This condition is associated with increased risk of malignancy. We report two cases, both female patients (both 56 years old) who were diagnosed with porcelain gallbladder. One presented with a pyogenic liver abscess and the other was diagnosed to have gallbladder carcinoma on the background of porcelain gallbladder with metastases in liver.

**Keywords:** Carcinoma, chronic cholecystitis, calcification, gallstones disease

## INTRODUCTION

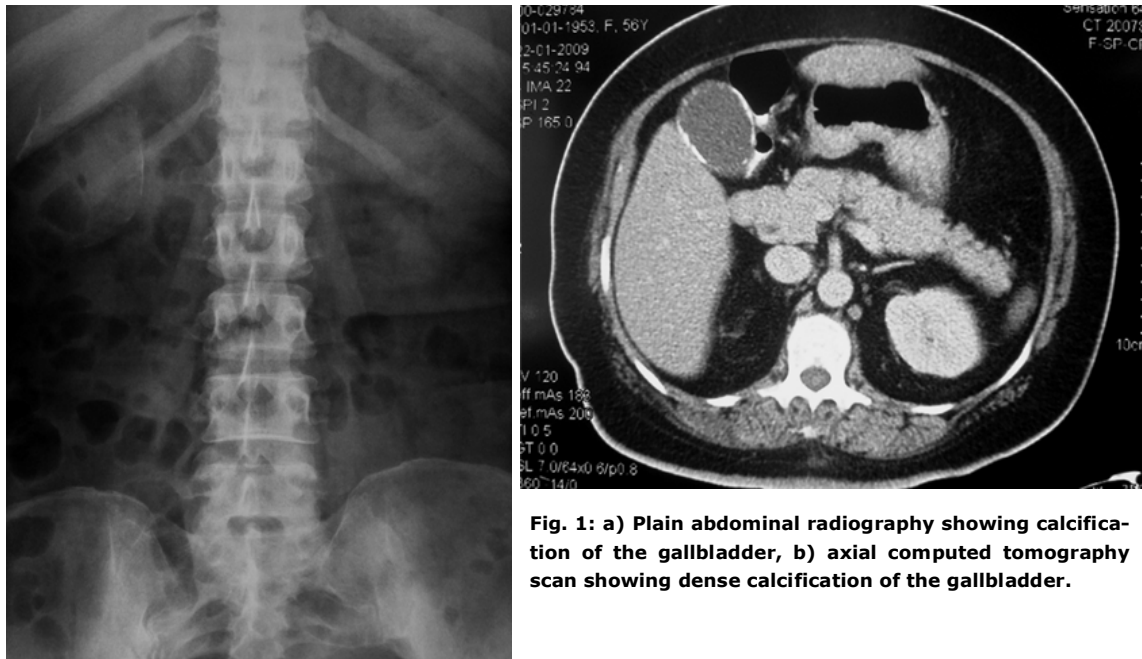
Porcelain gallbladder is an uncommon condition and is characterised by calcification of the wall of the gallbladder.<sup>1</sup> The wall of the gallbladder will be hard and brittle with a bluish white texture intra-operatively. The underlying pathogenesis is thought to be similar to gallstone disease although the exact underlying cause is not clear.<sup>2</sup> It is associated with increased risk of malignancy of the gallbladder.<sup>3</sup> We report two cases of porcelain gallbladder, one associated with liver abscess and another with gallbladder carcinoma.

**Correspondence author:** Vui Heng CHONG  
Department of Medicine,  
RIPAS Hospital  
Brunei Darussalam  
Tel: +673 2242424 Ext 5235,  
E mail: chongvuih@yahoo.co.uk

## CASE REPORT

**Case 1:** A 56-year-old Malay lady with a background of diabetes mellitus, hypertension and dyslipidemia was admitted after coming back from holidays with a six day history of fever with chills, rigors, night sweats, epigastric pain and anorexia. This was not associated with vomiting or any lower gastrointestinal complaints. There were no genitourinary or respiratory complaints. Examination of the abdominal, cardiovascular, respiratory and neurologically systems were all unremarkable.

Laboratory investigations showed leucocytosis with neutrophilia, transaminitis and elevated serum inflammatory markers. Serum erythrocyte sedimentation rate (ESR) was 106 mm/hr (normal <15) and C-reactive protein



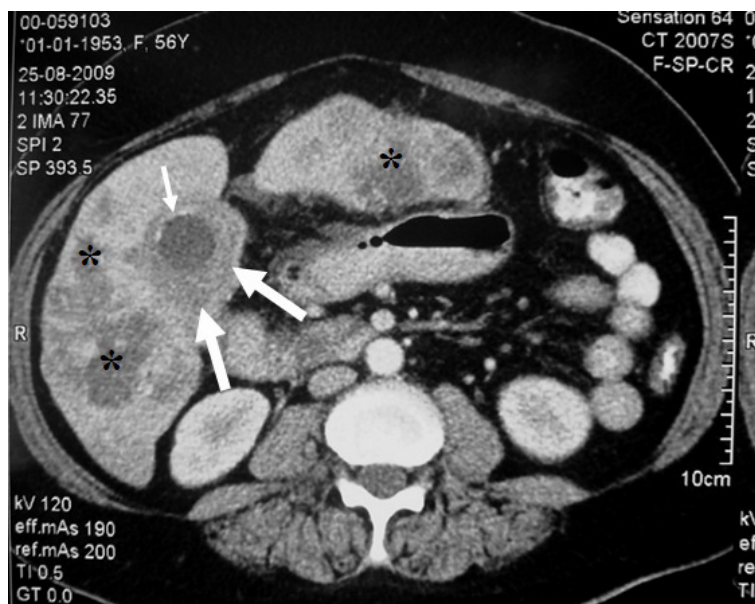
**Fig. 1: a) Plain abdominal radiography showing calcification of the gallbladder, b) axial computed tomography scan showing dense calcification of the gallbladder.**

(CRP) was greater than 33 mg/dl (normal <0.5). The initial abdominal ultrasound scan (USS) was reported as normal. She was empirically started on intravenous amoxicillin-clavulanic acid 1.2 gm t.i.d. to cover for gram negative sepsis. Blood culture later isolated *Klebsiella pneumoniae* that was sensitive to most antibiotics. Throat swab isolated *Streptococcal pneumoniae* that was also sensitive to most antibiotics. Urine culture was negative. Abdominal radiography showed a thin curvilinear calcification in the right upper quadrant consistent with a porcelain gallbladder (Figure 1a).

As the patient continued to spike temperature, a computed tomography (CT) scan of the abdomen was done. This showed a liver abscess in segments 2 and 8 and calcification of the gallbladder wall (Figure 1b). Her treatment was changed to ceftazidime and amikacin. She completed a total of six weeks of antibiotic therapies. Unfortunately, she declined any surgical intervention.

**Case 2:** A 56-year-old Malay lady with a background history of asthma was investigated for abdominal pain, vomiting and fullness of the abdomen of few days duration. She also had marginal weight loss.

Clinical examination was unremarkable. Laboratory investigations revealed cholestatic liver profiles. An ultrasound scan of the abdomen showed hepatomegaly with nodular lesions, thickened gallbladder wall with stones. She was then transferred to our institution for further evaluation. A computed tomography scan showed irregular thickened gallbladder with foci of calcification (Figure 2) and hepatic lesions consistent with metastases. A biopsy was positive for gallbladder primary. Tumour markers were elevated: Carcinoembryonic antigen (CEA) 135.57 IU/ml and carbohydrate antigen (CA) 19-9 >25,200 IU/ml. She was referred to the Oncology Unit for further management with a diagnosis of gallbladder carcinoma with metastases on a background of porcelain gallbladder.



**Fig. 2: Axial computed tomography scan showing thickened gallbladder carcinoma (big arrows) with calcifications (small arrows) and metastases to the liver (asterisks).**

## DISCUSSION

Porcelain gallbladder is considered a rare condition and is found in 0.06 to 0.08% of autopsies.<sup>1, 2, 4</sup> The term 'porcelain gallbladder' was coined in 1929 to describe the bluish discoloration and brittle consistency of a gallbladder that had an extensively calcified wall.<sup>5</sup> It is more common in females compared to males with a ratio of 5:1 and the mean age of diagnosis is between 38 to 70 years.<sup>6</sup>

Porcelain gallbladder is associated with increased risk of gallbladder malignancy. However, there are recent reports that the actual risk has been overestimated. Older studies have reported rates of incidence to be as high as 62%.<sup>5</sup> More recent studies reported lower rates between 5 to 12%.<sup>3, 6, 7</sup>

There are two types of calcification patterns seen in porcelain gallbladder. In one type, calcification is broad and continuous within the muscularis mucosa. On plain radio-

logy imaging, this appears as a large plaque-like lesion as seen in our first patient. The second type is characterised by the presence of multiple punctuate type calcification located in the glandular spaces of mucosa. This appears as granular calcification on radiography. This type of calcification gives the characteristic appearance of strawberry calcification. This has been reported to predict the risk of malignancy compared to those with diffuse intramural pattern.<sup>3</sup>

The exact underlying pathogenesis is not known but is strongly associated with chronic inflammation of the gallbladder. Most porcelain gallbladders (90%) are associated with gallstone disease<sup>2, 10, 11</sup> and hence, it has been postulated that the pathogenesis may be similar. Some consider it as a morphological variant of gallstone disease. Obstructions of the cystic duct lead to bile stagnation within the gallbladder and this is

followed by mucosal precipitation of calcium carbonate salts. Once chronic inflammation has set in, usually in the context of chronic cholecystitis, mural or mucosal calcification occurs and as the condition persists, it results in hardening and thickening of the gallbladder wall. This eventually results in formation of porcelain gallbladder. It is also believed that calcification is part of the natural progression of chronic inflammation resulting in scarring, hyalinisation and deposition of lime salts. However, not all cases of chronic inflammation of the gallbladder lead to porcelain gallbladder and not all cases of porcelain gallbladders have features chronic cholecystitis. This suggests that additional factors are required for progression to porcelain gallbladder.

Imaging is similar to those used for gallstone disease. Plain abdominal radiography show calcification ranging from focal specks to clumps or a diffuse pattern affecting the whole of the gallbladder. On ultrasound imaging, four patterns have been described; hyper echoic curvilinear calcification with posterior acoustic shadowing, biconvex curvilinear calcification, clumps or diffuse hyperechoic gallbladder. CT imaging is better in defining the types and locations of calcification. There may be associated features such as gallstones, thickened wall that may be diffuse as in chronic cholecystitis or focal, indicating possible malignancy.

Similar to gallstone disease, most patients with porcelain gallbladder are asymptomatic and are detected incidentally on imaging.<sup>12, 13</sup> Both our patients did not report any symptoms suggestive of gallstone disease. The first patient was diagnosed with pyogenic

liver abscess and imaging showed gallbladder calcification. Similarly, in the second patient, the porcelain gallbladder was diagnosed after imaging study.

Porcelain gallbladder may be a variant or complication of chronic cholecystitis. Gallbladder carcinoma is considered as a complication of porcelain gallbladder. The most common type of malignancy is adenocarcinoma which accounts for 80% of porcelain gall bladder associated cancers. Squamous cell and adenosquamous cell carcinoma have also been reported. In our first patient, porcelain gallbladder is associated with pyogenic liver abscess and this has not been previously reported.

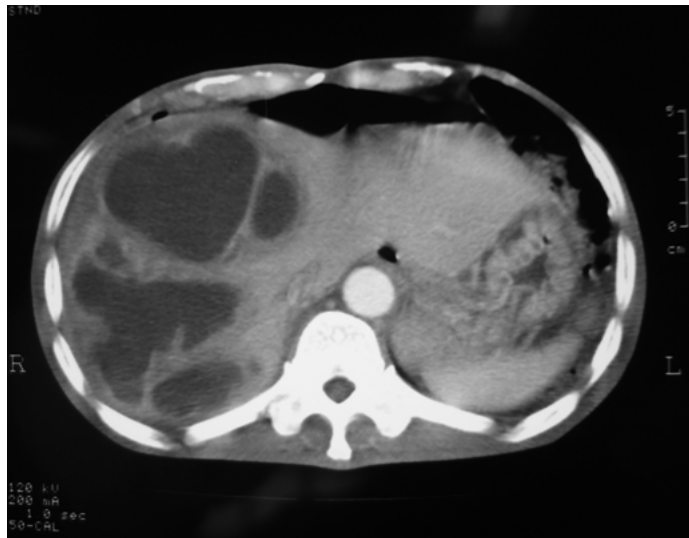The management of porcelain gallbladder is surgery due to the reported increased risk for malignancies.<sup>2, 3, 6</sup> Otherwise, patients should be monitored for changes in the wall thickness or irregularities. Some have reported either a laparoscopic or an open approach can be chosen based on the type of calcification.<sup>9</sup> Type I calcified gallbladder can be treated with laparoscopic cholecystectomy, whereas types II and III are better treated with open procedure.<sup>9</sup>

In conclusion, porcelain gallbladder is rare and associated with complications such as pyogenic liver abscess and gallbladder malignancies. Most patients are probably asymptomatic or with symptoms typical for gallstones diseases. Cholecystectomy should be considered.

## REFERENCES

- 1:** Kane RA, Jacobs R, Katz J, Costello P. Porcelain gallbladder: ultrasound and CT appearance. *Radiology.* 1984; 152:137-41.
- 2:** Polk HC Jr. Carcinoma and the calcified gall bladder. *Gastroenterology.* 1966; 50:582-5.
- 3:** Stephen AE, Berger DL. Carcinoma in the porcelain gallbladder: a relationship revisited. *Surgery.* 2001; 129:699-703.
- 4:** Towfigh S, McFadden DW, Cortina GR, et al. Porcelain gallbladder is not associated with gallbladder carcinoma. *Am Surg.* 2001; 67:7-10.
- 5:** Ashur H, Siegal B, Oland Y, Adam YG. Calcified gallbladder (porcelain gallbladder). *Arch Surg.* 1978; 113:594-6.
- 6:** Cornell CM, Clarke R. Vicarious calcifications involving the gallbladder. *Ann Surg.* 1959; 149:67-72.
- 7:** Kim JH, Kim WH, Yoo BM, Kim JH, Kim MW. Should we perform surgical management in all patients with suspected porcelain gallbladder? *Hepatogastroenterology.* 2009; 56:943-5.
- 8:** Gore RM, Yaghmai V, Newmark GM, Berlin JW, Miller FH. Imaging of benign and malignant disease of the gallbladder. *Radiol Clin N Am* 2002; 40:1307-23
- 9:** Kwon AH, Inui H, Matsui Y, Uchida Y, Hukuj J, Kamiyama Y. Laparoscopic cholecystectomy in patients with porcelain gallbladder based on the preoperative ultrasound findings. *Hepatogastroenterology.* 2004; 51:950-3.
- 10:** Wolfgang Dähnert. *Radiology Review Manual.* 6th Edition. Philadelphia: Wolters Kluwer Health; 2006:743.
- 11:** Liang HP, Cheung WK, Su FH, Chu FY. Porcelain gallbladder. *J Am Geriatr Soc.* 2008; 56:960-1.
- 12:** Cunningham SC, Alexander HR. Porcelain gallbladder and cancer: ethnicity explains a discrepant literature? *Am J Med.* 2007; 120:e17-8.
- 13:** Takeda K, Sekido H, Sugita M, Tanaka K, Endo I, Togo S. Porcelain gallbladder complicated with pancreas divisum. *J Hepatobiliary Pancreat Surg.* 2006; 13:580-3.

# HUMERUS



VHC

A Hearty Liver