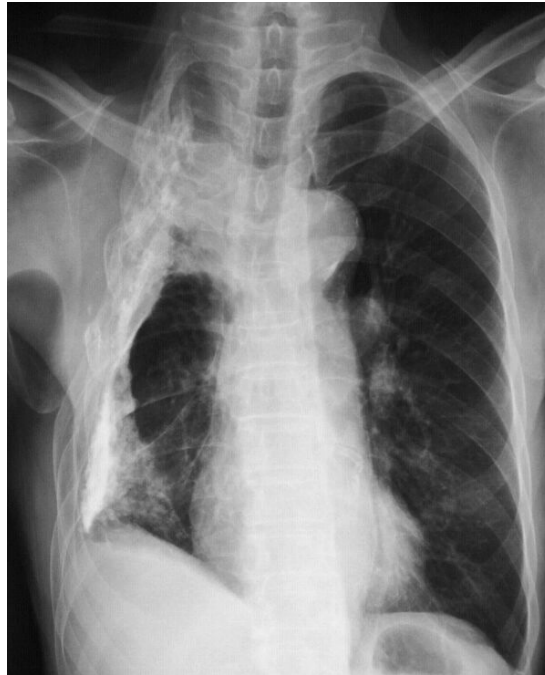


Chee Fui CHONG

An 82-year-old Chinese man was referred with a complaint of a chronic discharging sinus on the posterior chest wall for the previous three months. He gave a history of a surgical procedure that was performed on his chest wall for a pulmonary infection more than 20 years earlier. He had remained well until three months earlier and had been on regular courses of antibiotics to clear the discharging sinus. A chest radiograph showed a significantly narrowed right thoracic chest cavity with abnormal rib structure (**Panel**).

What is the surgical procedure and what was the pulmonary infection?

Answer: refer to page 281

Correspondence author: Chee Fui CHONG,
Thoracic Unit, Department of Surgery,
RIPAS Hospital, Bandar Seri Begawan BA1710,
Brunei Darussalam.
Tel: +673 2242424 Ext 8850/6280
E mail: chong_chee_fui@hotmail.com