

Peripheral ulcerative keratitis as the initial presentation of rheumatoid arthritis

Nadir Ali Mohamed ALI, Ruben MATHEW, Nayan JOSHI

Department of Ophthalmology, Raja Isteri Pengiran Anak Saleha Hospital, Bandar Seri Begawan, Brunei Darussalam

ABSTRACT

Rheumatoid arthritis is a chronic auto-immune disease that leads to persistent symmetrical polyarthritis mainly affecting the hands and feet. Significant extra-articular involvements can occur including the eyes. However, most extra-articular manifestations usually occur in the presence of joint changes or symptoms. We report an interesting case of a 62-year-old Malay lady who was referred severe ocular presentation, peripheral ulcerative keratitis that led to the diagnosis of rheumatoid arthritis. Interestingly, she had typical changes of rheumatoid arthritis in the hand but was not troubled by them.

Keywords: Cataract, hypopyon, peripheral ulcerative keratitis, rheumatoid arthritis

INTRODUCTION

Rheumatoid arthritis (RA) is a chronic auto-immune disease that causes persistent symmetric polyarthritis mainly affecting the hands and feet. Significant extra-articular involvement of organs such as the skin, heart, lungs, and eyes can occur. In the eye, it could involve the cornea, conjunctiva and sclera, but does not primarily affect the intra-ocular structures. Though peripheral ulcerative thinning is the commonest ocular feature of RA. It can also be caused by infectious and non-infectious systemic or local lesions. Systemic, non-infectious causes include collagen

vascular disorders such as Wegener's granulomatosis (now referred to as granulomatosis with polyangiitis (Wegener's), polyarteritis nodosa, relapsing polychondritis and systemic lupus erythematosus. ¹ Systemic infections causing corneal thinning include hepatitis and syphilis. Local non-infectious conditions include Mooren's ulcer and marginal keratitis, and local infections include herpes simplex and fungal keratitis. ²

The incidence of peripheral ulcerative keratitis (PUK) was reported as three cases per million per year in a study from the United Kingdom. ³ RA, however, has been reported as the most common collagen vascular disorder that causes PUK, accounting for 34% of non-infectious PUK. ⁴

Correspondence author: Nadir Ali Mohamed ALI
Department of Ophthalmology,
RIPAS Hospital, Bandar Seri Begawan BA 1710,
Brunei Darussalam
Tel: +673 8223690
E mail: nadiramali@hotmail.com

The usual presenting symptoms include ocular pain (most severe in cases of Mooren's ulcer) and redness. Other symptoms include inappropriate lacrimation, photophobia and decreased vision (usually secondary to corneal astigmatism). In cases of PUK, a detailed systemic examination is crucial to plan the appropriate work-up to detect and appropriately treat the underlying cause. We report a case of a patient who initially presented with severe PUK and responded favourably to topical and systemic corticosteroids and was later diagnosed to have RA.

CASE REPORT

A 62-year-old Malay lady was referred by her general practitioner to the Eye clinic of RIPAS Hospital, with a history of itchiness, and blurred vision in the left eye for a week prior to presentation. She had no known ocular or systemic illnesses. However, she had chronic and multiple joints pain with swelling, predominantly and bilaterally involving her wrist and knee joints, for more than 10 years. She never consulted a doctor for these complaints.

At presentation, her visual acuity was 6/12 in the right eye and only 'Counting Fingers' at half a metre in the left eye. The right eye was unremarkable except for an early

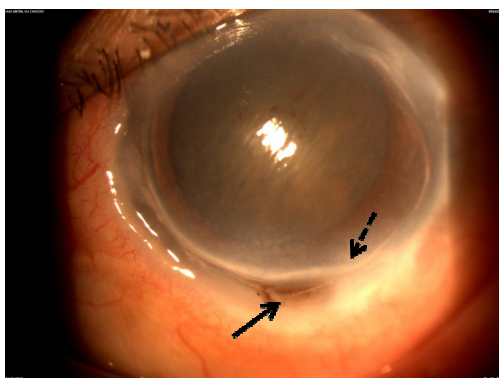


Fig. 1: A painful swelling with overlying of showing an intramuscular lesion.

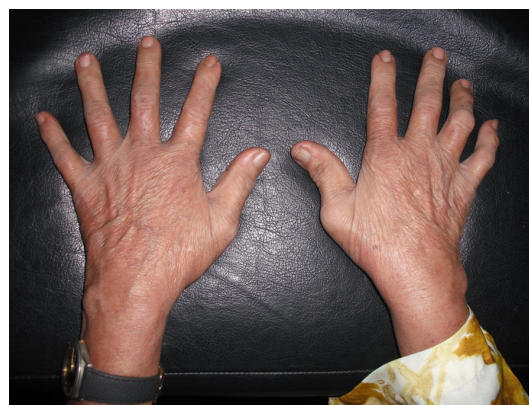

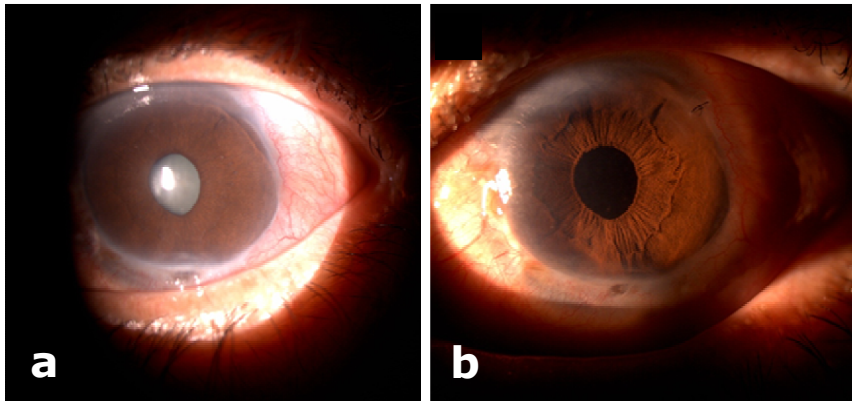
Fig. 2: Rheumatoid arthritis deformities of the hands: Z thumb, Boutonniere deformity and subluxation of the carpal bones.

cataract. The left eye showed a severe peripheral corneal thinning extending from One o'clock to 10 o'clock hour position in the limbus (Figure 1). The thinning stained with fluorescein indicating a lack of epithelial integrity. A 'self-sealing' corneal perforation with iris plug was seen at the six o'clock limbus with no aqueous leakage (negative Seidel test). The anterior chamber was deep and filled with inflammatory cells with an organised hypopyon inferiorly. There was no view of the posterior segment in the left eye.

Systemic examination showed asymmetrical Z-shape deformity of thumbs, and Boutonniere deformity, mainly in the right ring and little fingers and arthritic swelling of the wrists (Figure 2). Both her knees were also swollen and deformed.

Blood investigation revealed elevated erythrocyte sedimentation rate (ESR, 114 mm/hour), C-reactive protein (CRP, 3.19 mg/dl) and very high rheumatoid factor (1,024 IU/ml).

She was admitted with a working diagnosis of left perforated PUK secondary to



Figs. 3: Steroid induced cataract of the treated left eye, and b) post cataract surgery.

RA. She was commenced on intravenous ciprofloxacin 200mg twice daily, topical ciprofloxacin two-hourly, topical dexamethasone four times daily, topical atropine four times daily, topical artificial tears (Tears Naturale II®, Alcon) hourly and topical Solcoseryl three times daily as well as oral acetazolamide 250mg three times daily, with potassium supplements. She was also started on oral Prednisolone acetate 5mg daily, after rheumatology consult along with oral omeprazole 20mg per day.

The corneal thinning slowly resolved over the next 10 days and led to a thin layer of epithelium covering and adherent to the iris plug. The anterior segment inflammatory reaction and hypopyon totally resolved, and her visual acuity slightly improved to 'Counting Fingers' at two metres. Forty-eight hours later the intravenous ciprofloxacin was changed to a week course of oral therapy. Subsequently, she was discharged on oral prednisolone 5mg daily with oral Omeprazole 20 mg daily, topical ciprofloxacin six hourly, topical Dexamethasone six hourly and topical Atropine 1% twice daily in her left eye. The prednisolone treatment was continued for six weeks.

Over the next three months, the corneal thinning totally healed (except a small area at the six o'clock limbus at the site of the perforation that remained thin all through the period of management). However, the visual acuity in her left eye remained poor (Counting-fingers) due to dense steroid-induced cataract in that eye (Figure 3a). The right eye was unremarkable except for a mild cataract and steroid-induced rise in intraocular pressure which was controlled with topical Timolol Maleate 0.5% twice daily, and Latanoprost 0.005% once daily at night time.

Ten months after the initial management, a cataract surgery with intraocular lens implant was done in the left eye (Figure 3b). A post-operative left visual acuity of 6/36 (corrected to 6/9 with -5.50 DC at 110°) was achieved. The right eye visual acuity remained at 6/12.

DISCUSSION

PUK is progressive thinning of the peripheral cornea due to inflammatory process caused by hypersensitivity reaction elicited either by an autoimmune reaction or an exogenous factor such as bacteria. The underlying cause may be infectious or non-infectious. Infectious

causes include bacteria, viruses, fungi, and Chlamydia.⁵ The extracellular matrix of the cornea is composed of a series of highly organised lamellae of collagen fibrils embedded in a framework of glycosaminoglycans. Fibroblasts lie in the inter-lamellar region, and are responsible for the secretion of collagenase that breaks down the collagen facilitating the natural turnover for the corneal matrix. The balance between the level of collagenase and the tissue inhibitors of the enzyme is of great importance in the maintenance of the structure of corneal stroma. In eyes affected by PUK, a local imbalance between levels of a specific collagenase (MMP-1) and its tissue inhibitor (TIMP-1) has been described and it has been suggested that this imbalance is responsible for the rapid corneal keratolysis which is the hallmark of PUK.⁶

RA is the most common cause of non-infectious PUK accounting for about 34% of all cases.⁷ The presence of PUK in a patient with RA indicates the development of a potentially life-threatening disease. Foster *et al.* reported a mortality rate of 50% over a 10-year period in untreated RA patients with PUK.⁸ Our patient was not detected to have RA before this presentation. Despite the frequent attacks of arthralgia for more than 10 years, which indicates a long course of untreated RA, she did not seek medical advice.

In this case, clinical features at presentation suggested RA as the underlying cause. Blood investigation confirmed the diagnosis, with a four-figure high rheumatoid factor (1,024 IU/ml). The presence of PUK was associated with necrotising scleritis in 64% of cases.⁹ However, in our patient, there was no evidence of scleritis. The differential diagnosis

of PUK includes Mooren's ulcer and Terrien's marginal degeneration. Mooren's ulcer is a rapidly progressive, painful, ulcerative lesion of the peripheral cornea of unknown aetiology.¹⁰ Terrien's marginal degeneration is a rare disorder characterised by a slowly progressive painless thinning of the peripheral cornea with intact epithelium and sloping edge, and is also of unknown aetiology.¹¹ Although these conditions share a very similar clinical course, they can easily be differentiated. Mooren's ulcer usually starts superiorly then progresses circumferentially, with the advancing edge undermining the epithelium (shelving).¹⁰ It can be differentiated from PUK based on the morphological features and the severity of pain, which is intolerable in the former. Terrien's marginal degeneration, on the other hand, can be differentiated from PUK and Mooren's ulcer by the absence of inflammation and pain, and the intact epithelium. Our patient presented with unilateral, severe ulcerative lesion involving most of the peripheral cornea with systemic features suggestive of RA. Thus, she was diagnosed as PUK.

The main aims of treatment of PUK should involve reduction of inflammation, treatment of any associated infections, promotion of epithelialisation and prevention of stromal loss.⁵ Extensive lubrication with both eye drops and ointments helps promoting the epithelialisation and reducing the stromal loss, hence halting the thinning process. To reduce the inflammatory process, oral corticosteroids are the first line of treatment. Topical corticosteroids are relatively contra-indicated as they may interfere with the healing process, and may in some cases lead to perforation of the cornea. Our patient presented with

perforated cornea and hypopyon in the anterior chamber. We chose to start topical and systemic prednisolone to control both the systemic and the intraocular inflammation under antibiotic cover. She responded well to this treatment and complete recovery was achieved within 10 weeks of treatment without the need for any other immunomodulators.

The prolonged use of corticosteroids carries the risk of ocular side-effects such as steroid-induced glaucoma and cataract. In our patient, she developed cataract in the involved eye (which complicated her prognosis) and steroid induced glaucoma in the other eye. After complete recovery of the PUK, cataract surgery using phacoemulsification was done, with excellent visual outcome.

PUK associated with RA is a difficult-to-treat condition with significantly poor visual outcome. Treatment with lubricants, topical and systemic steroids is crucial, and can lead to good recovery in severely affected eyes.

We report this case due to atypical and severe ocular presentation which led to the diagnosis of RA. Furthermore, our patient had severe ocular complications such as extensive thinning leading to corneal perforation (self sealed with iris), severe uveitis, and hypopyon eventually resulting in very poor vision in the affected eye. Our case also highlights the importance of a high index of suspicion, immediate and aggressive management, and regular follow-ups to watch for short and long term sequelae. It shows that appropriate

management of secondary complications can improve the visual outcome.

REFERENCES

- 1: Shiuey Y, Foster CS. Peripheral ulcerative keratitis and collagen vascular disease. *Int Ophthalmol Clin.* 1998; 38:21-32.
- 2: Galor A, Thorne JE. Scleritis and peripheral ulcerative keratitis. *Rheum Dis Clin North Am.* 2007; 33:835-4.
- 3: McKibbin M, Isaacs JD, Morrell AJ. Incidence of corneal melting in association with systemic disease in the Yorkshire Region, 1995-7. *Br J Ophthalmol.* 1999; 83:941-3.
- 4: Silva BL, Cardozo JB, Marback P, Machado FC, Galvão V, Santiago MB. Peripheral ulcerative keratitis: a serious complication of rheumatoid arthritis. *Rheumatol Int.* 2010; 30:1267-8.
- 5: Yagci A. Update on peripheral ulcerative keratitis. *Clin Ophthalmol.* 2012; 6:747-54.
- 6: Riley GP, Harral RL, Watson PG, Cawston TE, Hazleman BL. Collagenase (MMP-1) and TIMP-1 in destructive corneal disease associated with rheumatoid arthritis. *Eye* 1995; 9:703-18.
- 7: Ladas JG, Mondino BJ. Systemic disorders associated with peripheral corneal ulceration. *Curr Opin Ophthalmol.* 2000; 11:468-71.
- 8: Foster CS, Forstot SL, Wilson LA. Mortality rate in rheumatoid arthritis patients developing necrotizing scleritis or peripheral ulcerative keratitis. Effects of systemic immunosuppression. *Ophthalmology.* 1984; 91:1253-63.
- 9: Tauber J, Sainz de la Maza M, Hoang-Xuan T, Foster CS. An analysis of therapeutic decision making regarding immunosuppressive chemotherapy for peripheral ulcerative keratitis. *Cornea.* 1990;9:66-73
- 10: Seino JY, Anderson SF. Mooren's ulcer. *Optom Vis Sci.* 1998; 75:783-90.
- 11: Jain K, Kumar S, Jain C, Malik VK. Terrien's marginal degeneration: an unusual presentation in an indian female. *Nepal J Ophthalmol.* 2009; 1:141-2.