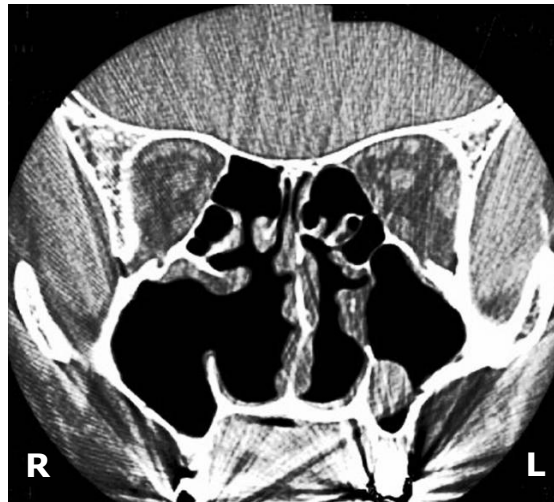


Saleh Khaled ABOUD and Asma ABDULLAH



A 59-year-old Chinese man presented with chronic nasal problems. He had had a post radical turbinate resection in 1984. His symptoms included chronic blocked nose, mouth breathing, nasal discharge, persistent postnasal drip, foul breath and right maxillary pain which had a significant negative impact on his quality of life. Despite treatment, his nasal symptoms showed no improvement. A cold spatula test revealed equal airflow bilaterally. Nasal endoscopy revealed very patent nasal cavities, absent middle turbinate and patent frontal, sphenoid and maxillary ostium. A computed tomography scan of the paranasal sinuses demonstrated left maxillary sinus mucosal thickening, a surgical defect in the medial wall of the right maxillary sinus and absent middle and inferior turbinates bilaterally (**Panel**).

What is the diagnosis?

Answer: refer to page 76

Correspondence author: Saleh Khaled ABOUD
Department of ORL-HNS, Faculty of Medicine,
University Kebangsaan Malaysia Medical Centre,
Jalan Yaakob Latif, Bandar Tun Razak 56000,
Kuala Lumpur Malaysia.
E mail: salehkh70@gmail.com