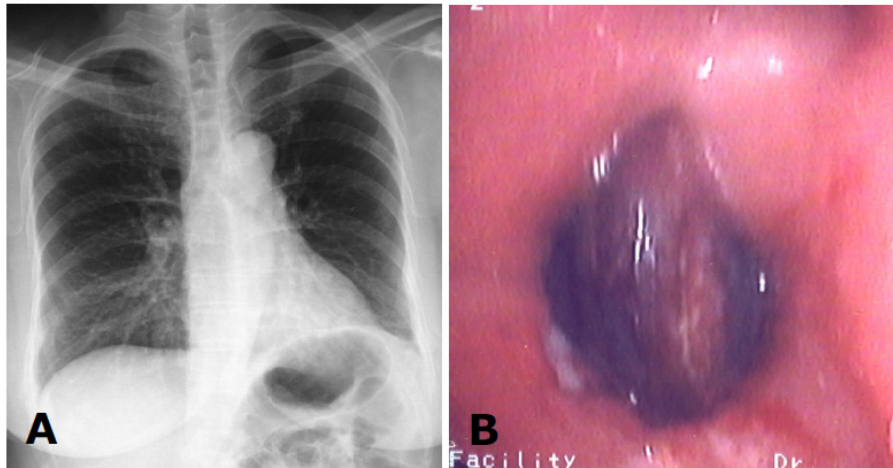


Panduru Venkata Kishore, Osama ABOUSEID, Khalizah JAMIL



A 50-year-old Chinese lady presented with chronic cough of more than four months duration and streaky haemoptysis for two weeks. She had previously visited various clinics and had received various courses of antibiotics without improvement. She was subsequently labeled as having bronchial asthma that failed to improve with bronchodilators. Her chest radiograph was abnormal (**Panel A**). A bronchoscopy was done (**Panel B**).

What is the diagnosis?

Answer: refer to page 144

Correspondence author: Panduru Venkata KISHORE
Division of Respiratory Medicine, Department of Medicine
RIPAS Hospital, Bandar Seri Begawan,
Brunei Darussalam
Tel: +673 2242424 Ext 5249
E mail: panduru.kishore@gmail.com