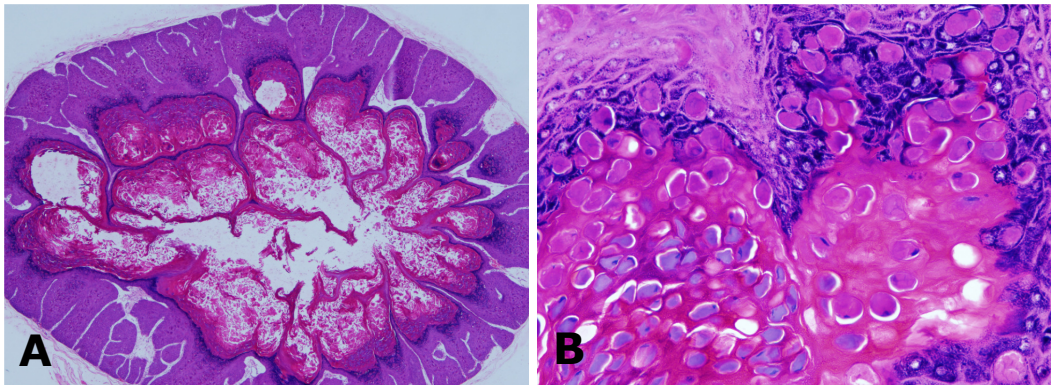


**Mohd Bahrin ALIUDDIN and Pemasari Upali TELISINGHE**



A 4-month-old boy presented with a 5mm skin lesion on the chest. Excision biopsy was performed and sent for histological examination. Low power microscope examination of the lesion showed a well circumscribed endophytic proliferation of squamous epithelium (H&E, x4) (**Panel A**). High power examination of the lesion showed characteristic intracytoplasmic eosinophilic inclusions (Henderson-Patterson bodies) (H&E, x40) (**Panel B**).

**Q: What is the diagnosis?**

**Answer:** refer to page 147

**Correspondence author:** Mohd Bahrin ALIUDDIN  
Department of Pathology, RIPAS Hospital,  
Bandar Seri Begawan BA 1710,  
Brunei Darussalam.  
Tel: +673 2242424 Ext 8827  
E mail: bahrin\_aliuddin@moh.gov.bn