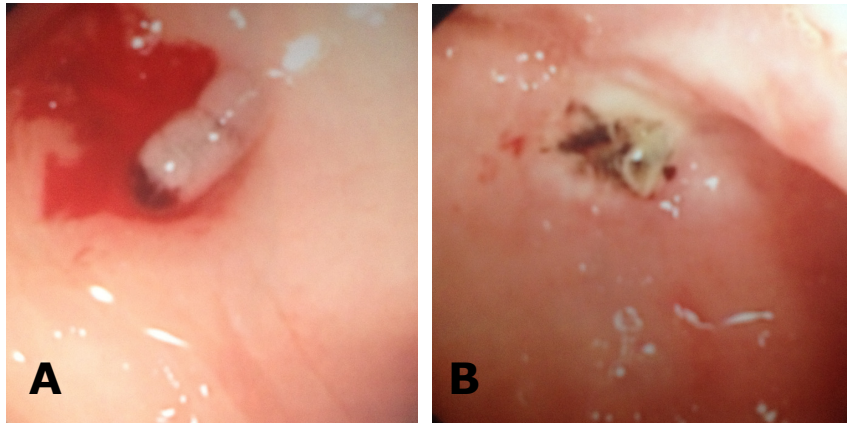


Ahmad Syadi MAT SAAD and Vui Heng CHONG



An elderly lady was admitted with anaemia and positive stool occult blood. She gave a history of passing fresh blood per rectum and was not on any antiplatelet and anticoagulation treatments medication. She was stabilised and underwent a colonoscopy after bowel preparation. The colonoscopy revealed a lesion seen in the sigmoid that was bleeding and this was treated (**Panels A and B**). The rest of the examination was normal.

Q: What is the diagnosis?

Answer: refer to page 280

Correspondence author: Vui Heng CHONG
Division of Gastroenterology and Hepatology,
Department of Medicine, RIPAS Hospital, Bandar
Seri Begawan BA 1710, Brunei Darussalam.
Tel: +673 2242424 Ext 5233
E mail: chongvuih@yahoo.co.uk