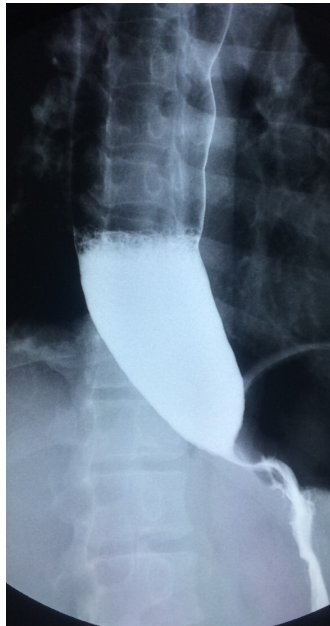


Vui Heng CHONG and Ian BICKLE



The middle aged gentleman presented with weight loss, retrosternal discomfort and dysphagia in the last few months. A barium swallow was done (**Panel**).

Q: What is the diagnosis?

Answer: refer to page 227

Correspondence author: Vui Heng CHONG
Department of Medicine, RIPAS Hospital,
Bandar Seri Begawan BA 1710,
Brunei Darussalam.
Tel: +673 2242424 Ext 5233
E mail: chongvuih@yahoo.co.uk