Traumatic posterior sternoclavicular joint dislocation: an uncommon injury

Khairul 'Azmi ABD KADIR and Ketan PANDE
Department of Orthopaedics and Trauma, RIPAS Hospital, Brunei Darussalam

ABSTRACT

Posterior sternoclavicular joint dislocation is an uncommon injury. Due to the relative unfamiliarity with its diagnosis, this condition is often not suspected leading to delayed or missed diagnosis. It can be associated with serious mediastinal complications. We report a case of a young man who presented with left sided chest and shoulder pain caused by left posterior sternoclavicular joint dislocation, following a road traffic accident. This was successfully managed with closed reduction.

Keywords: Sternoclavicular joint, traumatic dislocation, chest pain, posterior dislocation

INTRODUCTION

Sternoclavicular joint (SCJ) dislocation is an uncommon injury and posterior sternoclavicular joint dislocation (PSCJD) is more uncommon. [1] Its presentation can mimic other more common chest and shoulder injuries. Therefore, combined with its rarity and a relative unfamiliarity of the injury, its diagnosis is often not suspected, leading to delayed or missed diagnosis. PSCJD is associated with major mediastinal complications and even mortality. It is paramount to diagnose this injury at the time of presentation so that patient can be managed appropriately without delay. We present a case of left PSCJD following a road traffic accident.

Correspondence author: KA ABD KADIR
Department of Orthopaedics and Trauma,
RIPAS Hospital, Bandar Seri Begawan, BA 1710
Brunei Darussalam
Tel: +673 2242424 Ext 5615
E mail: khairulazmiabdkadir@gmail.com

CASE REPORT

A 28-years-old man who was previously fit and well presented to the Accident and Emergency Department as an unrestrained driver involved in a road traffic accident. He primarily complained of left sided chest and shoulder pain. He denied any respiratory distress, dysphagia or weakness and numbness of the upper limb. On examination, he was fully conscious and orientated, and all his vital signs were normal. Respiratory and cardiovascular examinations were unremarkable.

Musculoskeletal examination revealed severe generalised tenderness and swelling over the medial side of the clavicle with restricted range of movement of his ipsilateral shoulder secondary to pain. Both upper limbs had normal neurovascular status. The initial provisional diagnoses made in the Accident and Emergency Department were rib frac-

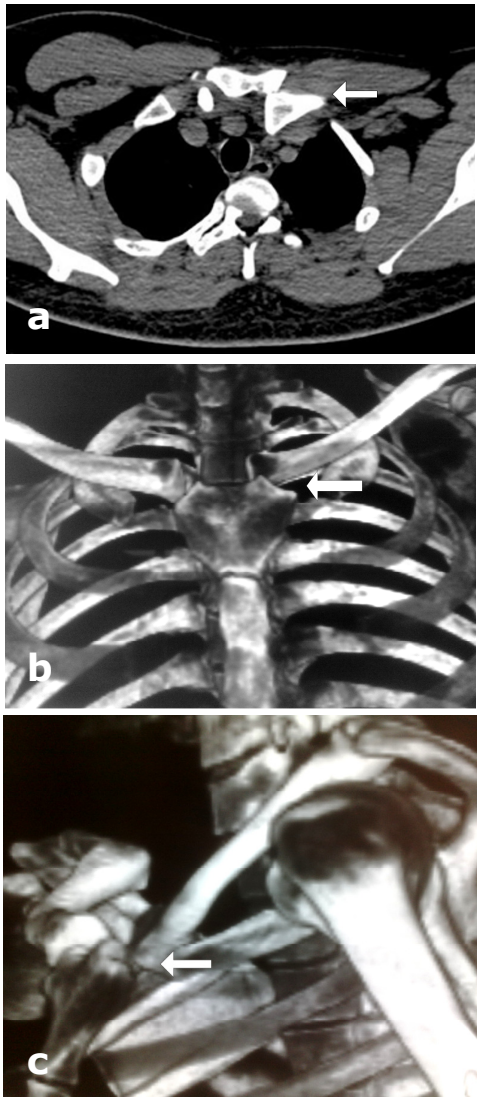

Figs. 1: a) Non-contrast CT axial view of the left sternoclavicular joint dislocation (arrow), b) reconstructed anteroposterior view (arrow), and c) reconstructed lateral view of the left sternoclavicular joint dislocation (arrows).

tures and left shoulder injury. However, plain radiograph of the chest and left shoulder did not demonstrate any abnormalities. Following this, an assessment by the orthopaedic team raised the possibility of left PSCJD due to suspicion of loss of normal protuberance over the left sternoclavicular joint (SCJ).

A non-contrast computed tomography (CT) of the chest and mediastinum showed a 2.3 cm left PSCJD with soft tissue swelling of 1.3 cm thickness behind the left SCJ (Figures 1a-c). Reconstruction images showed no other injuries and/or abnormalities in the mediastinal structures.

The patient underwent a successful closed reduction under general anaesthesia. A sandbag was placed underneath the supine patient at the interscapular region. The ipsilateral arm was extended to 20 degrees and abducted to 90 degrees after which a lateral traction was applied to his arm. The medial side of the left clavicle was hooked with fingers. Reduction was felt and the normal protuberance of the left SCJ was restored. The patient was then fitted with a figure of eight sling. Post-operative CT scan of the chest revealed good reduction of the left SCJ. He was discharged two days later without any complications. The patient was reviewed regularly in outpatient department. During the he last review six months after reduction, he had minimal pain and tenderness, good shoulder range of motion and no limitation to his daily activities.

DISCUSSION

PSCJD, an uncommon type of SCJ injury, was first described by Sir Astley Cooper in 1824. [2] It is more commonly seen in teenagers and young adults involved in major trauma, following a motorbike or a road traffic accident, or in certain contact sports such as rugby. [3]

The SCJ is the least frequently dislocated joint as it is stabilised by a number of ligaments, including the anterior and posterior sternoclavicular ligament, the interclavicular ligament and the costoclavicular ligament. The posterior sternoclavicular ligament is

more resilient to injury. Due to this, only 10% of SCJ dislocations are the posterior type. [4] Three grades of SCJ injuries have been described: grade 1 injuries are sprains caused by stretching of the aforementioned ligaments; grade 2 injuries are subluxations caused by tearing of all the ligaments except for the costaclavicular ligament; and grade 3 are tearing of all the ligaments with SCJ dislocation. A PSCJD requires a grade 3 injury. [2] It is mostly caused by either a significant force directed towards the anterolateral part of the SCJ or more commonly, an indirect posterolateral force at the shoulder with the ipsilateral arm flexed and adducted.

Due to its infrequent presentation, along with its signs and symptoms similar to that of other more common chest and clavicular injuries, PSCJD is often not suspected and its diagnosis is usually delayed or missed. PSCJDs usually present with significant sternal and shoulder pain with restricted range of motion of the upper limb following the mechanisms of injury stated above. The ipsilateral shoulder may point more anteriorly than the contralateral side. A depression at the SCJ may also be palpated but is easily missed due to swelling of overlying soft tissues. As in our case, this significant sign was initially missed. Moreover, due to a relative lack of familiarity with its diagnosis, the clinician has to have a high level of suspicion to look for this specific sign.

Plain chest radiograph is important in excluding other common causes of sternal and shoulder injuries but it is usually unhelpful in diagnosing PSCJD because the surrounding bony structures are obscuring the SCJ. Further specialised views, such as Serendipity, Hobbs, Heinig and Kattan projections have been proposed and may be helpful. [2, 5] However, CT imaging of the chest and mediastinum is the more sensitive test in visualising SCJ disruption indicating PSCJD. More importantly, injury to the neighbouring soft tissues and great vessels can also be evaluated. [3, 6]

Diagnosis of PSCJD is important due to the many mediastinal structures lying underneath the SCJ and the medial third of the clavicle. These include the trachea, oesophagus, internal jugular vein, vagus nerve, phrenic nerve, innominate artery and innominate vein. Injuries to these vital structures can cause tracheal obstruction, oesophageal compression, major vessels compression or laceration, thoracic outlet syndrome and haemopneumothorax, which can lead to serious morbidity and even mortality. [2, 7-9] Therefore, it is of utmost importance to do a thorough physical examination in patients suspected of PSCJD, checking for signs and symptoms such as shortness of breath, voice hoarseness, vital signs as well as upper extremity neurovascular status. Osteomyelitis of the clavicle and oesophageal fistula can also present as late complications. [7] Fortunately, our patient did not have any of these acute or late complications.

All PSCJD should be initially managed by closed reduction. Ideally, patients should be brought into the operating theatre so that the reduction can be performed under general anaesthesia. Closed reduction is successful in 80% of cases. [10] Senior orthopaedic and cardiovascular surgeons are advisable to be present in case of mediastinal complications or if closed reduction fails. The abduction-

extension technique, that was used in this case, is the most commonly described method for closed reduction. [10] An alternative method has been described by Buckerfield and Castle to treat PSJCD if the abduction-extension technique is unsuccessful. [11] In this method, a caudal traction is applied to the arm, which is adducted against the trunk. A direct pressure is then applied to both shoulders to force them posteriorly, depressing the lateral end of the clavicle, while levering the medial end of the clavicle superiorly over the first rib into its anatomic position. The patient is then immobilised using a figure of eight splint for three to six weeks.

In conclusion, PSCJD is a rare injury. It can present with clinical features, which may be subtle and often missed, and its diagnosis delayed or overlooked. However, a high level of suspicion is warranted if the patient's signs and symptoms are inconsistent with more common chest and clavicular injuries. CT scan of the chest is the investigation of choice. Due to its anatomical position, it can affect many vital mediastinal structures leading to catastrophic complications. Therefore, diagnosis and prompt reduction of posterior SCJ dislocation is important.

REFERENCES

1: MacDonald PB, Lapointe P. Acromioclavicular and sternoclavicular joint injuries. Orthop Clin N Am 2008; 39:535–45.

2: Fenig M, Lowman R, Thompson BP, Shayne PH. Fatal posterior sternoclavicular joint dislocation due to occult trauma. Am J Emerg Med. 2010; 28:385.e5-8.

3: Laffosse JM, Espié A, Bonnevialle N, et al. Posterior dislocation of the sternoclavicular joint and epiphyseal disruption of the medial clavicle with posterior displacement in sports participants. J Bone Joint Surg (Br) 2010; 92-B:103-9.

4: Dennis MG, Kummer FJ, Zuckerman JD. Dislocations of the sternoclavicular joint. Bull Hosp Jt Dis. 2000; 59:153-7.

5: Gilot GJ, Wirth MA, Rockwood Jr CA. Injuries to the sternoclavicular joint. In: Bucholz, Robert W, Heckman, James D, Court-Brown, Charles M eds. Rockwood and Green's Fractures in Adults. 6th ed., Philadelphia: Lippincott; 2006:1365-97.

6: Lim AKS, Lingaraj K, Das De S. Traumatic retrosternal dislocation of the sternoclavicular joint of a young adult with generalised ligamentous laxity. Injury Extra 2008 Sept; 39:302-4.

7: Mirza AH, Alam K, Ali A. Posterior sternoclavicular dislocation in a rugby player as a cause of silent vascular compromise: a case report. Br J Sports Med. 200; 39:e28.

8: Bennet AN, Edwards E, Kiss Z, Brukner P. Posterior sternoclavicular joint dislocation with brachiocephalic vein compression in elite hockey player. Injury Extra. 2006; 36:422-4.

9: Nakayama E, Noguchi T, Terada Y. Tracheal stenosis caused by retrosternal dislocation of the right clavicle. Ann Thorac Surg. 2007; 83:685-7.

10: Yeh GL, Williams GR Jr. Conservative management of sternoclavicular injuries. Orthop Clin North Am. 200; 31:189-203.

11: Buckerfield CT, Castle ME. Acute traumatic retrosternal dislocation of the clavicle. J Bone Joint Surg Am. 1984; 66:379-85.