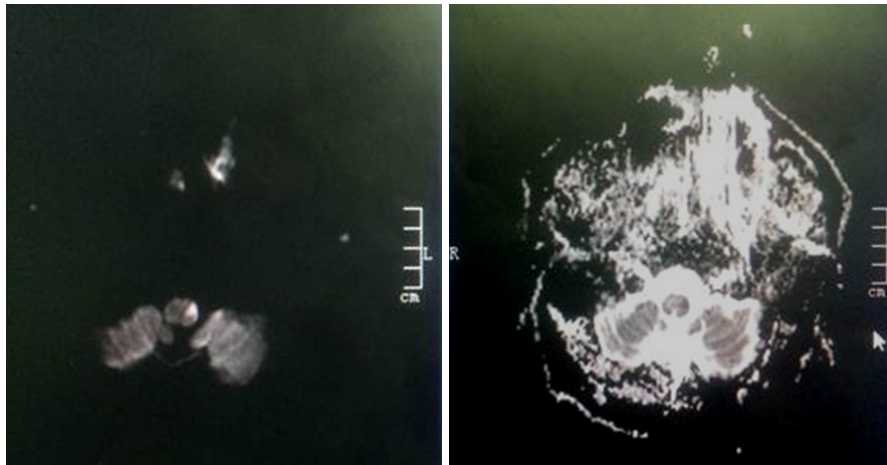


Matthew HON, Samuel JACKSON, Ian BICKLE



This patient presented with dysphagia, slurred speech, and ataxia. On examination, the patient was found to have lost pain and temperature sensation on the left side of the face. An MRI of the brain was performed (**Panel**).

What is the diagnosis?

Answer: refer to page 172

Correspondence author: Ian C BICKLE
Department of Radiology, RIPAS Hospital,
Bandar Seri Begawan BA 1710,
Brunei Darussalam.
Tel: +673 2242424 Ext 6503
E mail: firbeckkona@gmail.com