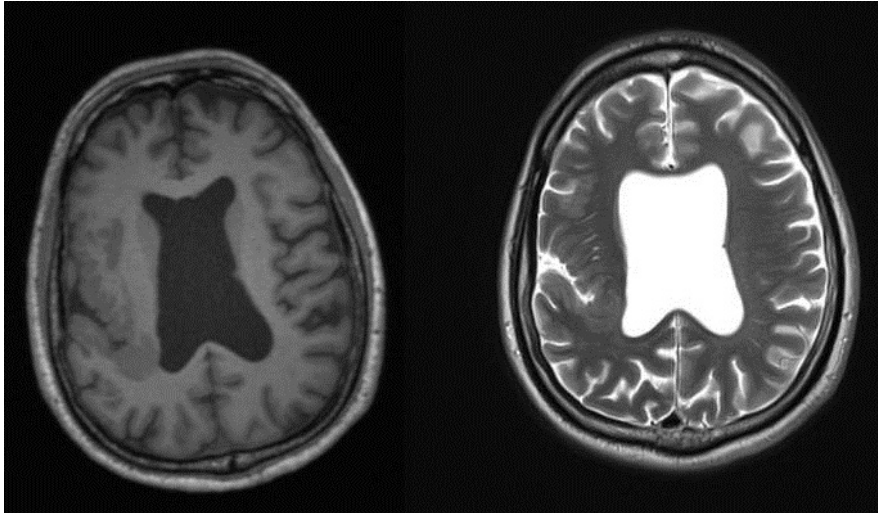


Siti Rozana ABDUL HAZIZ and Ian BICKLE



This 57-year-old man has a 17-year history of complex partial seizures on treatment. On neurological review, he states he had a recent single episode of sudden loss of consciousness with no post-ictal state. Computed tomography (CT) scan of the brain at the time of diagnosis was reported to be normal. A magnetic resonance imaging (MRI) of the brain was undertaken.

What abnormality on MRI is responsible for the patient's epilepsy?

Answer: refer to page 125

Correspondence author: Ian BICKLE
Department of Radiology, RIPAS Hospital,
Bandar Seri Begawan, BA 1710,
Brunei Darussalam.
Tel: +673 2242424
E mail: firbeckkona@gmail.com