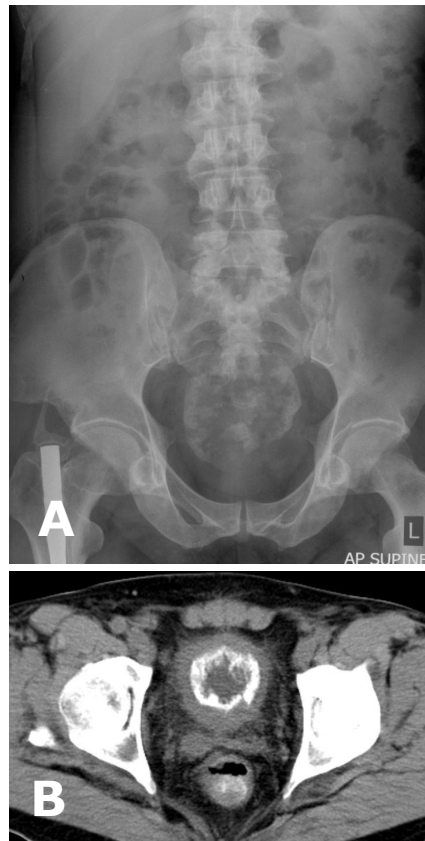


**Siti Kamariah CHE MOHAMED, Mohd Nazli KAMARULZAMAN, Radhiana HASSAN,
Hamid GHAZALI**



A 57-year-old man presented with severe suprapubic pain which was preceded by 6 months history of bladder irritation symptoms. No history of tuberculosis or any other medical or surgical problem, and no history of travelling abroad. A plain kidney, ureter and bladder (KUB) radiograph revealed an abnormality (**Panel A**) which was confirmed on a computed tomography scan (**Panel B**).

What is diagnosis?

Answer: refer to page 157

Correspondence author: Siti Kamariah CHE MOHAMED
Department of Radiology, Kulliyah of Medicine
International Islamic University Malaysia
Jalan Hospital Campus, 25100 Kuantan,
Pahang, Malaysia
E mail: skamariah08@gmail.com