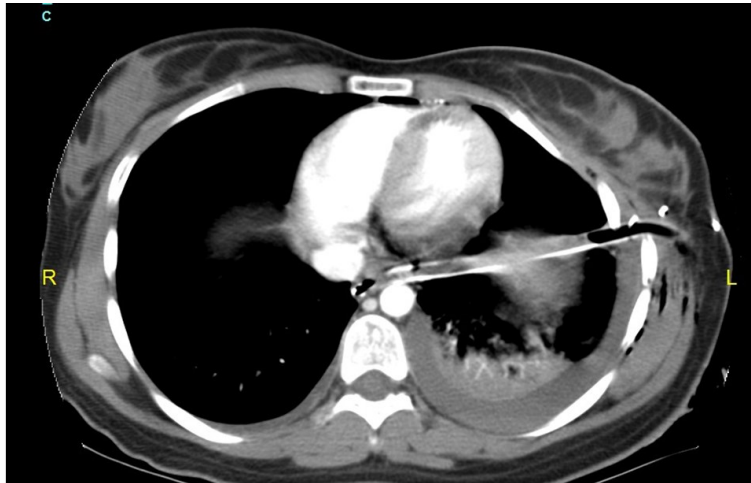


**Win Mar @ SALMAH, Irfan MOHAMAD, Wan Fadzlina WAN MUHD SHUKERI,
Ikhwan Sani MOHAMAD**



A 22-year-old lady involved in a motor vehicle accident, was brought to the emergency department with complaint of shortness of breath. Chest radiograph revealed a left haemothorax. A life saving procedure was done to the patient. Subsequent computed tomography scan was obtained after the procedure was completed (**Panel**). A shocking finding was revealed.

What is diagnosis?

Answer: refer to page 181

Correspondence author: Irfan MOHAMAD
Department of ORL-HNS, School of Medical Sciences,
Universiti Sains Malaysia Health Campus,
16150 Kota Bharu, Kelantan, Malaysia.
Tel : 609-7676424
E mail: irfankb@usm.my