A case of anorexia nervosa with severe bradycardia

Mohd Ridzuan MOHD SAID, Mohd Shawal Faizal MOHAMAD
Cardiology Unit, Department of Medicine, UKM Medical Centre, Kuala Lumpur, Malaysia

ABSTRACT

Anorexia nervosa is an eating disorder which is associated with significant morbidity and the leading cause of mortality attributed by anorexia nervosa apart from suicide is cardiac arrest. Cardiac complications are observed due to loss of cardiac mass and initially manifests with bradycardia. We reported the case of a 15-year-old boy who presented with AN and severe bradycardia. Electrocardiogram showed sinus bradycardia with first-degree atrioventricular block and noted several episodes of bradycardia from 24-hours holter monitoring. With a multidisciplinary team management and improvement of his nutritional status and body weight, his bradycardia resolved.

Keywords: Anorexia nervosa, bradycardia, cardiac abnormality, arrhythmia

INTRODUCTION

Anorexia nervosa (AN) has higher prevalence in western countries and commonly associated with female genders. [1] The prevalence of AN was 0.05% in Malaysia as reported in 1981. [1] Furthermore, the disease is associated with significant mortality in up to 10% from cardiovascular complication. [2] Physiological bradycardia is commonly observed in healthy athletes but pathological bradycardia can be an early sign of malnutritional state. [3, 4] We report the case of a 15-year-old boy who was referred with severe bradycardia and later diagnosed with AN. By treating his AN and resolving his malnutritional state, his bradycardia subsequently resolved.

CASE REPORT

A 15-year-old boy with no known medical illness, presented with history of self-induced vomiting, fear of gaining weight and lethargy. The symptoms occurred gradually within two years and were triggered by frequent teasing of his general appearance. He was obese with body weight of 65.1 kilogram and BMI of 30.9. He started skipping meals, exercised excessively and associated with self-induced purging behaviour. With this approach, he loses weight of 24 kilogram within three months. He also complained of lethargy, with reduced exercise tolerance but denied any syncopal attack, palpitation or giddiness. Despite losing significance amount of weight, he continued restricting his food intake for fear of gaining weight.

Clinically, he was pale and cachectic with BMI of 14.7 kg/m^2. His weight was 41.1 kilogram with a height of 167 centimetre. Vital signs recorded blood pressure of 90/68 mmHg with heart rate of 36 beats/min (BpM). Random dextrostix was 4.5 mmol/L. Chest auscultation was unremarkable with dual heart sound heard and no additional murmur. On abdomen examination, no organomegaly was noted. In addition, neck examination was

Correspondence author: Mohd Ridzuan MOHD SAID
Department of Medicine, Hospital Canselor Tuanku Muhriz, UKM Medical Centre, Jalan Yaacob Latiff 56000 Cheras, Kuala Lumpur, Malaysia
E mail: ridzuan.said85@gmail.com

normal with no palpable lumps.

Electrocardiography (ECG) revealed a sinus bradycardia rhythm with first degree AV block (Figure 1). There was Q wave at inferior leads (lead II, III and aVF) with deep T wave inversion on Lead V2. Otherwise, QTc was not prolonged.

Initial blood investigations showed elevated urea of 10.3 mmol/L with creatinine of 74.2 umol/L. Serum sodium and potassium levels were within normal range. Alanine aminotransferase (ALT) was elevated to 112 U/L with bilirubin of 19.6 umol/L. The serum albumin was 45 g/L with normal range of calcium, magnesium and phosphate. The Full blood count showed lymphopaenia with total white cell count of 3.1 $x10^9$/L and lymphocytes of 1.7 x10^9/L. The haemoglobin was 12.7 gm/dL with platelet of 164 $x10^9$/L. The thyroid function test was unremarkable with TSH of 1.5 uIU/ml and free T4 of 11.06 pmol/L.

A diagnosis of AN was made and his bradycardia and lymphopaenia were likely due to malnutrition. The patient was counselled about his diagnosis and supported with psychotherapy. He was assessed by dietitian and commenced on nutrition supplements with close monitoring of the electrolytes. Paediatric endocrinologist and psychologist were also involved with his care and emphasised on supportive psychotherapy.

A 24-hours Holter monitoring showed a heart rate varying from 32 to 123 BpM. Fourteen percent of the heart rate were bradycardic with longest pause of 2.1 sec. The longest bradycardia episode was observed around 8.14 pm with heart rate of 36 BpM and duration of 1,483 seconds. There were no episode of atrial flutter or fibrillation observed. In addition, echocardiography revealed preserved left ventricular function with ejection fraction of 53%. Cardiac valves were normal with no clot or pericardial effusion seen.

The patient recovery was lengthy and required constant motivation from a multidisciplinary team approach consisting of psychiatric, psychologist, nurses, dietitian and paediatric endocrinologist. After three weeks of treatment as inpatient, his body weight had improved to 43 kilogram and he was no long-

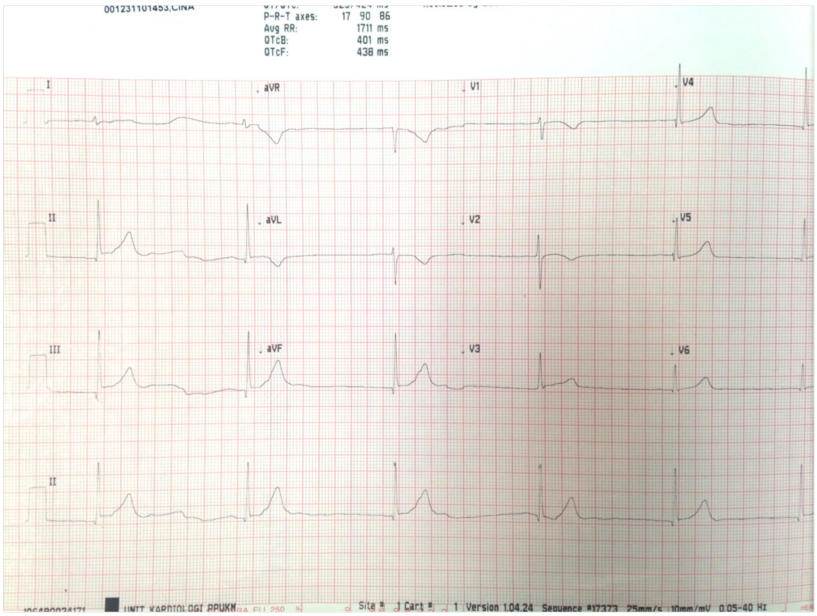

Fig. 1: ECG of the patient revealed a sinus bradycardia rhythm with Q wave at lead II, III and AVF.

er having fear of gaining weight. He was discharged with regular follow up with psychiatric clinic every fortnight. Upon discharge, his heart rate was 52 BpM with normal blood investigations.

Gradual improvement was observed in term of his body weight and social circumstances as well. He was currently enjoying his school life and denied any concern of gaining weight. During subsequent follow up a month later, he had gained weight back to 50.5 kilogram and documented heart rate was 75 BpM.

DISCUSSION

AN is a psychiatric condition and the disease is more common in female population with higher prevalence in western countries compared to non-western countries. [1] Even though the prevalence of AN in Malaysia is only 0.05%, this figure is rising in trend and thus warranted for early recognition.[1] Furthermore, Grover et al. reported that the rate of mortality within 10 years duration for anorexic patients is up to 10% and among the leading cause of mortality nonetheless is due to cardiovascular complication such as sudden cardiac death. [2]

Early recognition of AN may prove a perplexing task but with the introduction of Diagnostic and Statistical Manual of Mental Disorder (DSM-V), early recognition of AN is feasible. Furthermore, additional information gained from physical examination may distinguish severe malnutrition, which is at higher risk of morbidity. Maitland *et al.* outlined on danger signs such as hypothermia, lethargy or hypoglycaemia were predictors for early mortality and 80% of the mortality cases had documented bradycardia and hypothermia. [5]

Clinical examination of patients with AN especially in early stage may be unremarkable however Grover et al. reported that with AN. [2] The proposed mechanism for bradycardia observed in this group of AN patients is due to acute drastic weight loss leading to reduce metabolism with an adaptive vagal hyperactivity and increase parasympathetic response, thus reducing heart rate. The loss of cardiac muscle bulk from starvation also contributed to the bradycardia. [2]

Evaluation of severe bradycardia among AN patients are perplexing as sinus bradycardia is routinely observed in malnutrition state but may indicate a significance risk factor of sudden cardiac death. [3, 5] Nonetheless, invasive investigations for bradycardia including cardiac imaging or even coronary angiography may need further justification as bradycardia perhaps is a normal phenomenon. [3, 6] Therefore, risk stratification is necessary and ECG is pivotal in giving clues for any cardiac abnormalities. Presences of prolong QTc interval, atrio-ventricular block or ventricular arrhythmias justified for further evaluation especially in symptomatic patients with syncopic attacks, palpitation or giddiness. [6] 24-hours holter monitoring or constant telemetry should be offered for high risk patients.

In addition, echocardiogram provided a valuable assessment in term of prognostication as low values of Left Ventricular (LV) Mass or elevated LV myocardial performance index are associated with increased risk of cardiac death. [6]

With a multidisciplinary management, improvement of body weight will generally led to resolution of the cardiac abnormalities and this has been previously reported. [7] Mont *et al.* had demonstrated on improvement of left ventricular mass by more than 20% together with higher cardiac output after recovered from malnourished state. [7] In addition, normalization of heart rate or ECG changes were also observed after weight gain by 25% and indicating the reversibility of cardiac dysfunction in patients with AN. [7]

In conclusion, management of AN required multidisciplinary approach, and anorexic patients presenting with severe bradycardia requires further cardiac assessment to exclude cardiac morphology abnormalities. In most cases of AN with bradycardia, the cardiac dysfunction will generally resolved with improvement in the patients nutritional status.

REFERENCES

1: Makino M, Tsuboi K, Dennerstein L. Prevalence of eating disorders: a comparison of Western and non-Western countries. Medscape Gen Med. 2004; 6:49.

2: Grover CA, Robin JK, Gharahbaghian L. Anorexia nervosa: a case report of a teenager presenting with bradycardia, general fatigue, and weakness. Pediatric Emer Care. 2012; 28:174-7.

3: Liu EF, Chen L, Gao BX. Sinus bradycardia: normal phenomenon or risk factor? Evaluation based on recent evidence. J Insurance Med. 2012; 43:102-11.

4: Portilla MG. Bradycardia: an important physical finding in anorexia nervosa. The Journal of the Arkansas Medical Society. 2011; 107:206-8.

5: Maitland K, Berkley JA, Shebbe M, Peshu N, English M, Newton CR. Children with severe malnutrition: can those at highest risk of death be identified with the WHO protocol? PLoS medicine. 2006; 3:e500.

6: McCallum K, Bermudez O, Ohlemeyer C, Tyson E, Portilla M, Ferdman B. How should the clinician evaluate and manage the cardiovascular complications of anorexia nervosa? Eating Disorders. 200614:73-80.

7: Mont L, Castro J, Herreros B, et al. Reversibility of cardiac abnormalities in adolescents with anorexia nervosa after weight recovery. J Am Acad Child Adolescent Psy. 2003; 42:808-13.