

LOH Chow Chin, Hanizasurana HASHIM, Nor Fariza NGAH

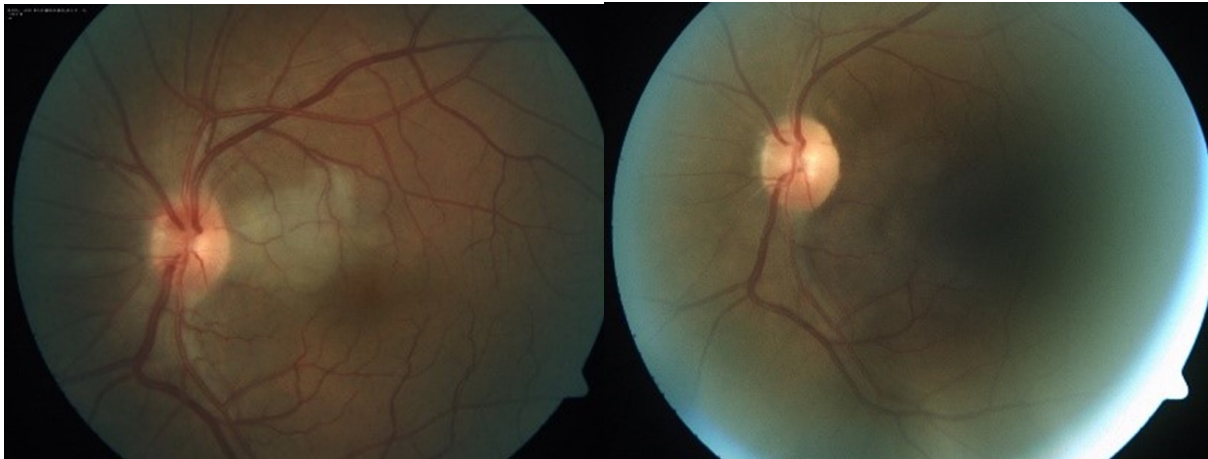


Figure 1. Left eye fundus photo at event time.

Figure 2. Left eye fundus post 1 month event (after treatment).

A 46 year old gentlemen with no previous medical comorbidities presented with acute, painless visual reduction in the left eye for 12 hours duration. He was a chronic smoker who smoke 30 cigarettes per day for the past 20 years. He denied associated headache, jaw claudication, nor other connective tissue disease symptoms. On clinical examination, his visual acuity was counting finger at a distance of 1 feet on his left eye and 6/9 on his right. Findings of anterior segment examinations of both eyes were unremarkable. Fundus examination showed a patch of whitening of the retina left of the optic nerve (Figure 1). Immediate ocular massage using Goldman 3 mirror, applying self-rebreathing bag and anterior chamber paracentesis were performed. His vision improved after the manoeuvres. Fundus examination 1 month later showed resolution of the patch of whitening in the retina (Figure 2).

What is diagnosis?

Answer: refer to page 78

Correspondence author: Dr Chow Chin LOH,
Department of Ophthalmology, Blok A-703, Kuaters Hospital
Selayang, Lebuhraya Selayang-Kepong, 68100, Batu Caves,
Selangor, Malaysia.
Tel: +6016-4382338, Fax: +603-61371652,
email: flcc10@yahoo.com
