

Wardati Sahimin YAKOB and Mohin MOMIN

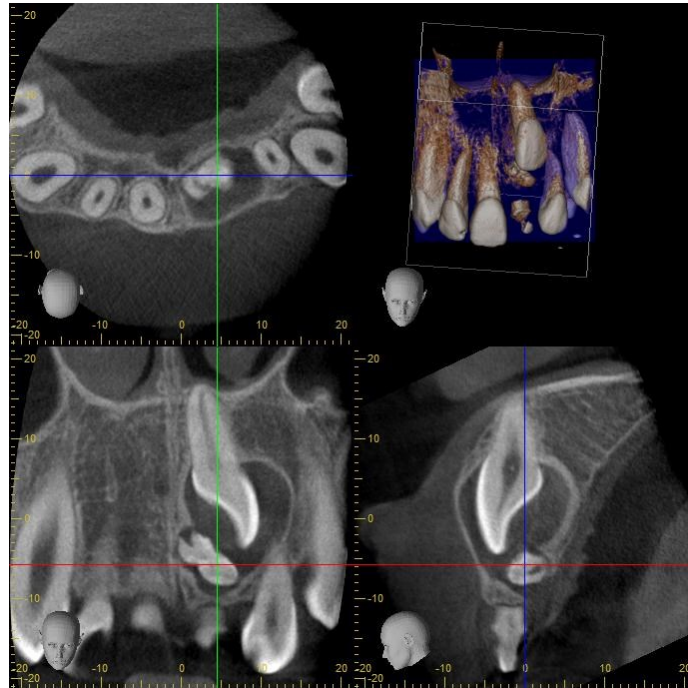


Figure 1

A 12 year old boy presented with an over-retained maxillary left primary central incisor. Clinical examination revealed the presence of all his permanent incisors except the maxillary left permanent central incisor. The crown of the maxillary left permanent central incisor was palpable on the buccal mucosa, apical to the over-retained tooth. Special investigation including cone-beam CT scan of the area of interest was requested. One of the snapshot images of the cone-beam CT is shown here.

What is the diagnosis?

Answer: refer to page 145

Correspondence author: Dr. Hj Dyg Wardati Sahimin Binti Hj Yakob, Associate Dental Specialist, National Dental Centre, Berakas, Bandar Seri Begawan, Brunei Darussalam.
email: wardati.yakob@moh.gov.bn